

RESEARCH ARTICLE

Chest X-Ray Evaluation of Cavitory Lesions among Pulmonary MDR-TB Patients

Resta Farits Pradana^{1*}, Yusuf S. Nawawi^{2,3}, Bambang Satoto¹

¹Radiology Department, Kariadi Hospital, Faculty of Medicine, Diponegoro University, Semarang, Indonesia

²Department of Public Health and Community Medicine, Faculty of Medicine, Syiah Kuala University, Banda Aceh, Indonesia

³Radiology Department, Moewardi Hospital, Faculty of Medicine, Sebelas Maret University, Surakarta, Indonesia

*Corresponding author: resta.farits@gmail.com

Received 22 October 2017; Accepted 11 August 2018

DOI: 10.23886/ejki.6.8468.

Abstract

The objective of this study is to know the relationship between MDR-TB treatment to the changes in diameter and thickness of cavity wall on chest X-ray (CXR) 6 month and 12 months post treatment. This study was conducted in MDR-TB clinic in Kariadi Hospital, Semarang on January 2013-December 2016. We examine cavitory lesions, evaluated with CXR in pulmonary MDR-TB patients before and after 6 and 12 months of treatment course. Subjects who had been diagnosed as pulmonary MDR-TB and had received MDR-TB treatment for at least 12 months were chosen. Subjects characteristics and cavities features i.e. cavity number, diameter and wall thickness from initial and follow-up CXR 6 and 12 months of treatment were retrieved. A total of 43 patients of MDR-TB, consisted of 22 males and 21 females, was recruited. Most of the subjects aged 31-50 year old and presented with single cavity. The cavitory lesions showed significant reduction over 6 and 12 months of follow up based on CXR ($p < 0.001$) for both diameter and wall thickness. Both diameter and wall thickness changed significantly from initial to 6 months ($r = -0.87$, $p < 0.001$), initial to 12 months ($r = -0.87$, $p < 0.001$), and 6 months to 12 months ($r = -0.84$, $p < 0.001$), respectively. In conclusion, CXR as a useful diagnostic instrument that can be used to evaluate pulmonary TB, in primarily low resource setting.

Keywords: MDR-TB; cavitory lesions; chest X-ray.

Evaluasi Lesi Kavitas dengan Foto Toraks pada Pasien MDR-TB Pulmoner

Abstrak

Tujuan penelitian ini adalah untuk mengetahui hubungan pengobatan MDR-TB terhadap perubahan diameter dan ketebalan dinding kavitas pada foto toraks setelah 6 bulan dan 12 bulan pengobatan. Penelitian dilakukan di klinik MDR-TB Rumah Sakit Kariadi, Semarang pada bulan Januari 2013-Desember 2016. Lesi kavitas pada pasien MDR-TB dievaluasi dengan foto toraks sebelum dan setelah 6 dan 12 bulan terapi. Subyek adalah pasien MDR-TB pulmoner dan telah menjalani terapi selama sekurangnya 12 bulan. Informasi yang dikumpulkan meliputi karakteristik subyek dan gambaran kavitas berupa jumlah, diameter, dan ketebalan dinding pada foto toraks pada awal dan evaluasi bulan ke-6 dan ke-12 setelah terapi. Sebanyak 43 pasien MDR-TB terdiri atas 22 laki-laki dan 21 perempuan disertakan memiliki karakteristik berikut: sebagian besar subyek berusia 31-50 tahun dan memiliki kavitas tunggal. Berdasarkan foto toraks lesi kavitas menurun signifikan 6 bulan dan 12 bulan setelah pengobatan ($p < 0,001$) baik diameter dan ketebalan dinding ($r = -0,87$; $p < 0,001$) awal dibandingkan 12 bulan ($r = -0,87$; $p < 0,001$) dan 6 bulan dibandingkan 12 bulan ($r = -0,84$; $p < 0,001$). Disimpulkan foto toraks merupakan instrumen diagnostik yang berguna untuk mengevaluasi TB pulmoner khususnya pada situasi dengan sumber daya terbatas.

Kata kunci: MDR-TB; lesi kavitas; foto toraks.

Introduction

Multi-drug resistant tuberculosis (MDR-TB) is caused by *Mycobacterium tuberculosis* resistant to isoniazid (INH) and rifampicin (RMP), with or without resistance to other antituberculosis drugs. MDR-TB represents a serious challenge in TB control globally.¹ The World Health Organization has introduced continually updated treatment recommendation and integrated management of drug-resistant TB patient since 2008, yet the number of MDR-TB keeps raising.^{2,3} In 2015, there were an estimated 480,000 new cases of MDR-TB and an additional 100,000 people with rifampicin-resistant TB (RR-TB) who were also newly eligible for MDR-TB treatment. Globally, in 2015, an estimated 3.9% of new cases and 21% of previously treated cases had MDR/RR-TB. Indonesia ranks second among 30 high TB burden countries, with more than one million new cases and incidence rate of 395 per 100,000 populations in 2015. It is estimated 2.8% of new cases with MDR/RR-TB and 16% of previously treated cases had MDR/RR-TB in Indonesia.⁴

Previous studies have shown multiple cavities are common in MDR-TB patients.⁵⁻⁸ The cavity is formed when the caseic necrosis melts and exudes through the bronchial branch leaving the cavity in the lung. The cavity wall layer causes a decrease in the amount of drug from the bloodstream that can penetrate the source of the infection.^{9,10} In addition, high bacillary titers in the cavity increase the likelihood of forming a population of drug-resistant bacteria. Therefore, the lung cavity is a biological basis for drug-resistant TB.¹¹ The cavity of pulmonary TB can be cured without leaving a trace or leaving persistent residual changes which may affect lungs structurally and functionally.^{12,13}

Chest X-ray (CXR) is one of the rapid and noninvasive diagnostic tools to evaluate patients with pulmonary TB.¹⁴ Cavitory lesion is one of hallmark features present in pulmonary TB which can be evaluated by imaging modality. The objective of this study is to know the relationship between MDR-TB treatment to the changes in diameter and thickness of cavity wall on CXR during 6 month and 12 months of treatment. This study serves as a preliminary investigation to assess cavitory changes by using CXR among patients with MDR-TB.

Methods

This retrospective study was conducted based on secondary data traced from medical record of MDR-TB patients. Patients who were initially diagnosed as MDR-TB and referred to MDR-TB clinic in Kariadi Hospital, Semarang, and received MDR-TB treatment

from January 2013 to December 2016 were recruited. Diagnosis of MDR-TB was based on GeneXpert examination and bacterial culture and drug-sensitivity test from sputum samples by following standard diagnostic algorithm in Indonesia.¹⁵ The standardized drug regimen was given to each patients for at least 18 months according to standard treatment guideline in Indonesia.¹⁵ We selected study subjects who were HIV-negative and had received MDR-TB treatment for at least 12 months, had performed initial CXR and at 6 and 12 months of MDR-TB treatment, with cavitory lesions from initial CXR. Patients with incomplete baseline data and CXR, irregular treatment or drop out cases, comorbid diseases, non-standard MDR-TB regimen were excluded.

Baseline information of MDR-TB patients including age and sex were collected. Information of cavitory lesions number and size (wall thickness and diameter) was retrieved from CXR examination. The cavity diameter (in mm unit) is a measure of the diameter of the lucent area in the pulmonary consolidation zone, mass, or nodule, surrounded by an inner wall of varying thickness.

The cavity wall thickness (in mm unit) is a measure of the thickness of the wall surrounding the lucent area in the pulmonary consolidation zone, mass, or nodule. CXR was performed using computer radiography (CR), MasterView DICOM 4.5.6.ink program in CR, X-Ray General Purpose Hitachi R-6CC210 125 kv, 200 MA, and Kodak digital 14 x 17 in. The reading of CXR radiograph was performed by 2 radiologists. This study and its procedure was reviewed and approved by Health Research Ethical Commission Faculty of Medicine Diponegoro University and Kariadi Hospital, with approval letter number 87/EC/FK-RSDK/III/2017.

Statistical analyses were conducted using SPSS 23.0 (SPSS Inc., Chicago, IL, USA). Two-tailed p-values <0.05 were considered to indicate statistical significance. The general characteristics of the study subjects were shown descriptively. Normality test were performed to know the distribution of data. Non-parametric repeated measures and post-hoc tests were used to explore the association between MDR-TB treatment and cavitory lesions of MDR-TB patients.

Results

A total of 43 patients of MDR-TB were recruited as study subjects. There were slightly higher number of males compared to females (22 vs 21), with most of the subjects aged 31-50 year old and presented with single cavities. The baseline characteristics of patients were shown in Table 1.

Table 1. Characteristics of Study Subjects

Characteristics	n	%
Gender		
Male	22	48.8
Female	21	51.2
Age group		
≤30	13	30.3
31-50	25	58.2
>50	5	11.6
Number of cavities		
Single	24	55.8
Multiple:		
2	12	27.9
3	7	16.3

There were a total of 69 cavities out of 43 study subjects retrieved from initial CXR examination. The cavitory lesions showed a significant reduction over 6 and 12 months of follow up based on CXR ($p < 0.001$) for both diameter and wall thickness (Table 2 and Figure 1 and 2). There were 64 and 50 cavities persisted after 6 and 12 months of follow up, respectively. It appeared that both diameter and wall thickness changed significantly from initial to 6 months ($r = -0.87$, $p < 0.001$), initial to 12 months ($r = -0.87$, $p < 0.001$), and 6 months to 12 months ($r = -0.84$, $p < 0.001$), respectively (Table 3).

Table 2. Characteristics of Cavity Diameter and Wall Thickness

Characteristics	Median (min-max)	Mean ± SD	p-value*
Cavity diameter			
Initial	15.16 (2.86-70.00)	19.26 ± 15.40	<0.001
6 months	12.32 (0.00-64.47)	15.53 ± 14.20	
12 months	8.16 (0.00-57.00)	11.69 ± 13.20	
Wall thickness			
Initial	1.50 (0.50-7.20)	1.80 ± 1.17	<0.001
6 months	0.98 (0.00-4.30)	1.19 ± 0.93	
12 months	0.70 (0.00-2.82)	0.75 ± 0.71	

*Friedman test

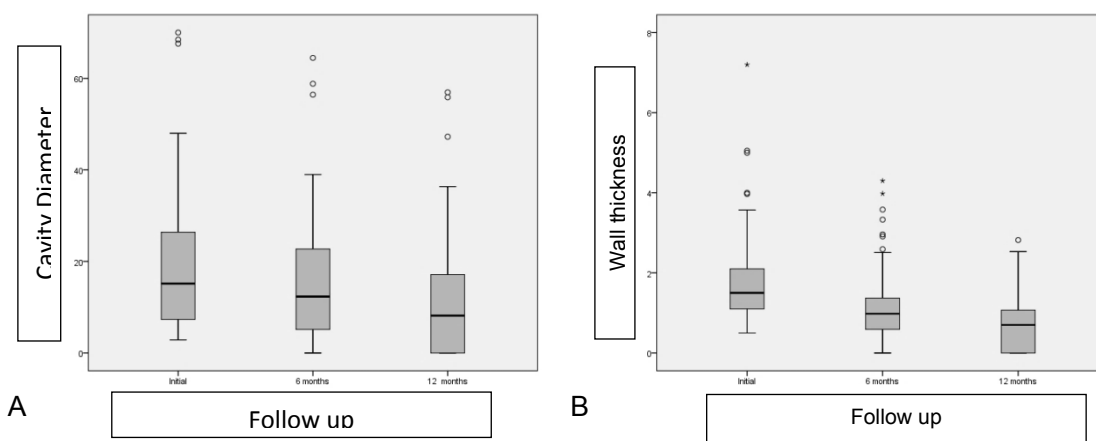


Figure 1. Boxplot Cavity Diameter (A) and Wall-Thickness (B) from Initial CXR and Follow up at 6 and 12 Months of Treatment

Table 3. Post-Hoc Analysis of Cavity Diameter and Wall-Thickness

Comparison	Diameter			Wall-thickness		
	Z	R	p-value	Z	r	p-value
Initial – 6 months	-7.22	-0.87	<0.001	-7.21	-0.87	<0.001
Initial – 12 months	-7.22	-0.87	<0.001	-7.22	-0.87	<0.001
6 months – 12 months	-6.96	-0.84	<0.001	-6.96	-0.84	<0.001

*post-hoc Wilcoxon test

Discussion

MDR-TB represents a major challenge to reach of global TB control. MDR-TB treatment is much more difficult with current treatment of MDR-TB which based on more drugs given for a longer period of time; thus more toxic, much less satisfactory outcomes and more expensive. Special management is needed to ensure optimum treatment outcomes. Serial chest radiography has been recommended for monitoring treatment response, in addition to acid-fast bacillus smear of serial sputum.⁴ Therefore, the precise interpretation of various radiographic responses in the context of treatment response is meaningful.

Multiple cavities is one of the most common significant features in MDR-TB patients which can be evaluated by radiography modalities.⁵⁻⁸ Treatment strategies targeting patients with cavitory TB have the potential to improve cure rates and reduce disease transmission.^{9,16} In present study, we found 44.2% (19 of 43 patients) presented with multiple cavities based on our initial CXR examination which comparable with other studies.^{7,8} Pulmonary cavitation represents the classic hallmark of post-primary tuberculosis resulted from certain elements of host inflammatory response to *M.tuberculosis* leading to tissue damage and ultimately TB cavity formation. TB cavity is associated with very high bacillary burden and thus infectivity and antimycobacterial-drug resistance.^{5,6,9,16}

We found a significant difference of diameter and wall thickness of the cavity between the baseline and during the follow up at 6 and 12 months of treatment, as shown by significant downtrend with highly negative correlation between initial and during treatment over follow up period. Another study by Kim et al.¹³ and Bombarda et al.¹⁷ investigated the changes of radiographic features following the treatment as evaluated by radiographic imaging. Both studies presented an improvement of radiographic features over the course of treatment, including the reduction of the size of cavities.

The subjects in both studies however,

demonstrated persistent cavities at the end of treatment. Some cavities remained after treatment, with thinning walls, which represents the inactivation of that specific process.^{13,17} Majority of the cavities usually resolve as linear or fibrotic lesions or healed completely. However, complete anatomical clearing of the cavities after adequate treatment does not always occur. In present study, a total of 50 of 69 cavities persisted at the end of follow up, even though the cavities became smoother and smaller after the treatment.

This present study showed the utilization of serial CXR as a tool to evaluate treatment response. Different with present study, Kim et al. and Bombarda et al.¹⁷ utilized computed tomography (CT) scan to evaluate treatment response.^{13,17} Given its higher sensitivity over CXR, CT-scan is frequently employed in the diagnosis and follow-up of TB especially to confirm absence of active infection, when CXR result is vague. However, neither national nor international guideline puts CT-scan as routine examination, which may be due to limited availability, high cost and relatively high dose exposure to radiation.¹⁸

There were several limitations identified in this study. We did not examine the associated factors which may affect cavitory lesions development (such as age, diabetes and other concomitant diseases), thus the findings presented in this study could be potentially confounded. In present study, we only assessed for cavity as our main interest radiographic features, while other features may also worth to look up. CXR may not the best modality to asses cavitory lesions given its inherent low diagnostic sensitivity. Further research needs to be conducted with CT-scan examination to obtain more accurate measurement. However, given the vast availability of CXR, this examination could be beneficial in low-moderate resources setting.

Conclusion

CXR is a useful diagnostic instrument that can be used to evaluate pulmonary TB in primarily low resource setting. Our study showed a significant

reduction of cavitory lesions as evaluated with CXR among pulmonary MDR-TB patients who received treatment.

Conflicts of Interest

No potential conflict of interest relevant to this article was reported.

Acknowledgements

We would like to thank to all physicians and nurses of MDR-TB clinic and radiographers of Radiology Department, Kariadi Hospital for their support upon this work. This works received no funding or financial support to disclose.

References

- Nathanson E, Nunn P, Uplekar M, Floyd K, Jaramillo E, Lönnroth K, et al. MDR tuberculosis — critical steps for prevention and control. *N Engl J Med*. 2010;363(11):1050–8.
- WHO. WHO treatment guidelines for drug-resistant tuberculosis. Geneva: WHO; 2016.
- WHO. Companion handbook to the WHO guidelines for the programmatic management of drug-resistant tuberculosis. Geneva: WHO; 2014.
- WHO. Global tuberculosis report 2016. Switzerland: WHO; 2016.
- Li D, He W, Chen B, Lv P, Kwon O, Kim Primary multidrug-resistant tuberculosis versus drug-sensitive tuberculosis in non-HIV-infected patients: comparisons of CT findings. *PLoS One*. Public Library of Science. 2017;12(6):e0176354.
- Kempker RR, Rabin AS, Nikolaishvili K, Kalandadze I, Gogishvili S, Blumberg HM, et al. Additional drug resistance in *M.tuberculosis* isolates from resected cavities among patients with multidrug-resistant or extensively drug-resistant pulmonary tuberculosis. *Clin Infect Dis*. 2012 ;54(6):e51-4.
- Cha J, Lee HY, Lee KS, Koh W-J, Kwon OJ, Yi CA, et al. Radiological findings of extensively drug-resistant pulmonary tuberculosis in non-AIDS adults: comparisons with findings of multidrug-resistant and drug-sensitive tuberculosis. *Korean J Radiol*. 2009;10(3):207–16.
- Kim S, Min J, Lee J. Radiological findings of primary multidrug-resistant pulmonary tuberculosis in hiv-seronegative patients. *Hong Kong J Radiol*. 2014;17(1):4–8.
- Yoder MA, Lamichhane G, Bishai WR. Cavitory pulmonary tuberculosis: the holy grail of disease transmission. *Curr Sci*. 2004;86(1).
- Gadkowski LB, Stout JE. Cavitory pulmonary disease. *Clinical Microbiology Reviews*. American Society for Microbiology (ASM). 2008.p.305–33.
- Kaplan G, Post FA, Moreira AL, Wainwright H, Kreiswirth BN, Tanverdi M, et al. *M.tuberculosis* growth at the cavity surface: a microenvironment with failed immunity. *Infect Immun*. American Society for Microbiology; 2003;71(12):7099–108.
- Chakaya J, Kirenga B, Getahun H. Long term complications after completion of pulmonary tuberculosis treatment: a quest for a public health approach. *J Clin Tuberc Other Mycobact Dis*. 2016;3:10–2.
- Kim S, Lee J, Lee J. Changes in chest CT findings of pulmonary tuberculosis after linezolid treatment. *Springerplus*. Springer; 2013;2:615.
- World Health Organization. Chest radiography in tuberculosis detection. Summary of current WHO recommendations and guidance on programmatic approaches. Geneva: WHO; 2016.
- Kementerian Kesehatan Republik Indonesia. Petunjuk teknis manajemen terpadu pengendalian tuberkulosis resistan obat. Jakarta: Kementerian Kesehatan RI; 2014.
- Ong CWM, Elkington PT, Friedland JS. Tuberculosis, pulmonary cavitation, and matrix metalloproteinases. *Am J Respir Crit Care Med*. American Thoracic Society; 2014;190(1):9–18.
- Bombarda S, Figueiredo CM, Seiscento M, Terra Filho M. Pulmonary tuberculosis: tomographic evaluation in the active and post-treatment phases. *Sao Paulo Med J*. Associação Paulista de Medicina; 2003;121(5):198–202.
- Bhalla AS, Goyal A, Guleria R, Gupta AK. Chest tuberculosis: radiological review and imaging recommendations. *Indian J Radiol Imaging*. 2015;25(3):213–25.